

# Proceedings of the 55th Annual Convention of the American Association of Equine Practitioners

December 5–9, 2009, Las Vegas, Nevada  
Program Chair : Nathaniel A. White



## ACKNOWLEDGMENTS

Dr. David D. Frisbie, Educational Programs Committee Chair  
Carey M. Ross, Scientific Publications Coordinator

Published by the American Association  
of Equine Practitioners

[www.aaep.org](http://www.aaep.org)

ISSN 0065-7182

© American Association of Equine Practitioners, 2009

# Review of Castration Complications: Strategies for Treatment in the Field

Liberty M. Getman, DVM, Diplomate ACVS

Castration is a commonly performed procedure, but it has a relatively high complication rate. Complications encountered can include post-operative swelling and edema, infection, hemorrhage, everted scrotum, peritonitis, penile damage, and hydrocele. Prompt recognition of a complication and the institution of appropriate therapy are essential for the treatment of these complications. This report reviews treatments that can be performed in the field and indicates the cases that should be referred for more aggressive treatment. Author's address: Department of Clinical Studies, University of Pennsylvania, School of Veterinary Medicine, New Bolton Center, Kennett Square, Pennsylvania 19348; e-mail: libertyg@vet.upenn.edu. © 2009 AAEP.

## 1. Introduction

Castration is the most common surgical procedure performed by equine veterinarians in the field. Although the surgery is technically easy to perform, the complication rate associated with it is relatively high with 20–38% of horses experiencing a complication.<sup>1,2</sup> Additionally, equine castration complications are the most common cause of malpractice claims against veterinarians in North America.<sup>3</sup> Pre-operative identification of risk factors for the development of complications can ensure that proper measures are taken to reduce these risks. This can help eliminate some complications, but even with appropriate pre-operative evaluation and proper surgical technique, complications can still occur. Therefore, prompt recognition of complications and quick application of appropriate therapy are essential for the treatment of post-operative complications. This may include treatment that can be performed in the field or in some cases, treatment that is best performed at a referral center.

## 2. Post-Operative Swelling and Edema

Post-operative swelling and edema of the prepuce and scrotal area are the most common “complications” of equine castration, although some degree of swelling develops in almost every horse after castration. This generally peaks 3–4 days after surgery and resolves completely in 10–12 days. Swelling beyond this time or swelling associated with clinical signs such as a stiff gait or reluctance to move or urinate is abnormal (Fig. 1). This is often caused by failure to remove enough scrotal skin, failure to stretch the skin and SC tissue after castration, or inadequate exercise after castration, any of which allows the scrotal incision(s) to close prematurely and excess fluid to accumulate. Older horses are also reported to be more prone to developing excessive edema after castration than younger horses.<sup>4</sup>

Swelling beyond the initial post-operative period is also suggestive of an infectious process, which should be treated appropriately (see below) if suspected. Horses with swelling that is not suspected to be infectious in origin can be treated at the farm

---

## NOTES

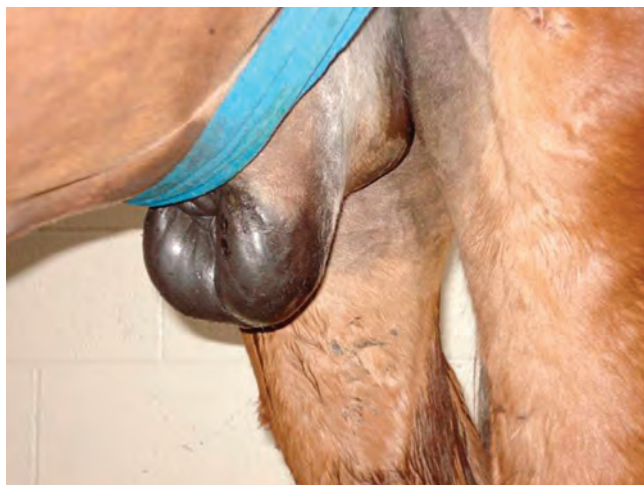

Fig. 1. Horse with excessive post-operative swelling and edema after castration.

by establishing drainage and administering non-steroidal anti-inflammatory drugs (NSAIDs). The horse is sedated, the area is aseptically prepared, and the incision is manually opened and stretched using sterile gloves. It is imperative that the owner follow this treatment up by instituting daily (or twice daily) exercise to prevent premature closure of the incision. If left untreated, excessive swelling can lead to the development of paraphimosis, surgical site infection, and dysuria.

### 3. Infection

Infection is the second most common complication after equine castration; 3–20% of horses are reported to experience this complication.<sup>1,2</sup> Clinical signs can occur anywhere from days to years after surgery, and they include fever, scrotal/preputial swelling, lameness, and incisional discharge. Use of ligatures around the spermatic cord has been associated with a higher risk of post-operative infection.<sup>2,4</sup> Different forms of post-castration infection exist. Champignon, or infection caused by *Strepto-*

*coccus sp.*, is characterized by the presence of a purulent discharge from the spermatic cord stump surrounded by a mound of granulation tissue. This form was more common historically when non-sterile materials were used as ligatures. Scirrhus cord refers to chronic infection of the spermatic cord stump, typically with a *Staphylococcus sp.* In these cases, the scrotal incision heals, but the infected stump continues to enlarge and abscess; eventually, a draining tract develops. This may take months to years to become evident. The abscessed stump is palpable externally as a firm mound of tissue in the inguinal area (Fig. 2). In some cases, the abscesses can involve the entire spermatic cord stump through the inguinal ring and into the abdomen; in these horses, the abscessed stump can be palpated per rectum as a firm mass.

Any horse with a fever and scrotal/preputial swelling after castration should be treated as a post-castration infection until proven otherwise. Treatment in the field can be successful, especially if it is instituted early. This should consist of opening and stretching the incision using the aseptic technique as described above, lavage of the incision with sterile isotonic fluids (with or without dilute antiseptics), and administration of broad-spectrum antimicrobials. This treatment protocol has been found to be more effective than doing any of the above components alone.<sup>1</sup> The incision may need to be reopened periodically, and exercise should be instituted to prevent premature closure of the wound. NSAIDs should be used for analgesic and anti-inflammatory purposes. It is also advisable to obtain a deep sample from the incision for bacterial culture and sensitivity testing before the administration of antimicrobials to direct future therapy. This can be done after an aseptic preparation of the area around the incision by inserting a sterile cotton-tipped applicator deep into the incision while wearing sterile gloves and then placing it into culture media. Empirical broad-spectrum antimicrobial therapy can then be initiated pending these results. The most common isolate from post-cas-

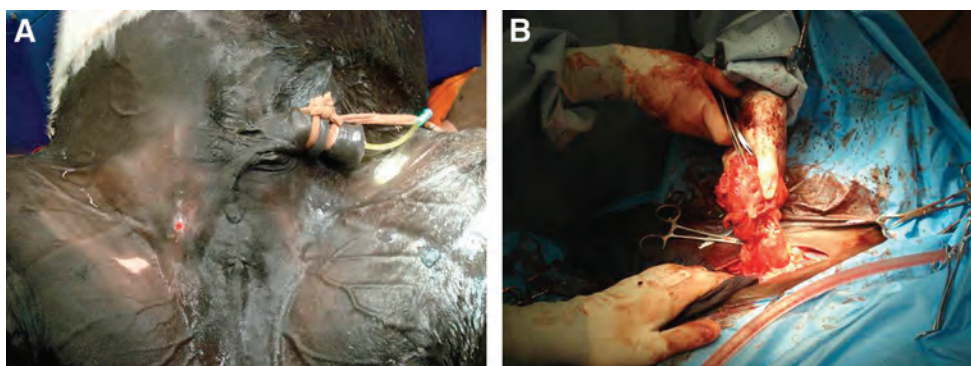


Fig. 2. (A) A pony with a chronic infection of the spermatic cord after castration (“scirrhus cord”). Note the swelling that is represented by a firm mass and the draining tract. (B) Infected spermatic cord stump resected at surgery.

tration infections is *Streptococcus zooepidemicus*, but other bacteria including *Staphylococcus sp.*, Enterobacteriaceae, and *Pseudomonas* are also isolated frequently. In our hospital, oral antimicrobials such as trimethoprim sulfamethoxazole, chloramphenicol, or doxycycline are often used initially with good results; however, if the horse is showing signs of systemic illness, it may be advisable to use broad-spectrum IV antimicrobials such as potassium penicillin or a cephalosporin in combination with an aminoglycoside for initial therapy.

Most infections will resolve with this therapy at the farm if treated early. For those that do not resolve or in cases where signs do not occur until months after the castration, then referral to a surgical center is warranted, because these cases will require surgical resection of the infected tissue for complete resolution. Other cases that warrant referral are those with systemic signs of sepsis or endotoxemia and those where infection with a *Clostridial sp.* is suspected. Although rare, tetanus and botulism can occur in unvaccinated horses, and wound infections with other *Clostridial sp.* can cause necrotizing cellulitis, myositis, and systemic endotoxemia. Infections with any *Clostridial sp.* can result in serious illness and death, and if suspected, these horses should be referred as soon as possible.

#### 4. Hemorrhage

Some bleeding is usual for the first ~5 min after the emasculator is removed (or the horse stands up from anesthesia); however, hemorrhage in the form of a fast drip or a stream beyond 15 min is excessive and should be addressed.<sup>4,5</sup> The most common source of post-castration hemorrhage is the testicular artery; less commonly, the hemorrhage is from a scrotal vessel (branches of the external pudendal vessels) or a vessel within the cremaster muscle. Hemorrhage typically occurs because of improper application or function of the emasculators, including non-perpendicular placement of the emasculators on the spermatic cord, inclusion of scrotal skin within the emasculators, tension of the spermatic cord during emasculation, premature release of the emasculators, and use of emasculators that are too sharp.

Initial treatment can (and should) be performed in the field and is often successful in identifying and eliminating the source of hemorrhage. In the acute situation, the horse should be sedated if it is systemically stable, and the spermatic cord stump should be identified and inspected for the source of hemorrhage. This may require injection of local anesthetic into the stump. If the stump is found to be the source of the hemorrhage, then it should be emasculated again, and a transfixation ligature with large, absorbable suture material<sup>a</sup> should be placed proximal to the emasculator while it is in place for additional hemostasis after its removal. If the stump is retracted too far within the scrotal incision

to be emasculated, then it can be grasped with crushing forceps, which are then left in place for 24–48 h. If the source of hemorrhage is determined to be a scrotal vessel, then the vessel should be clamped and ligated routinely. For hemorrhage originating from the cremaster muscle, emasculation and placement of a transfixation ligature should be performed. If the source of the hemorrhage cannot be identified, then the scrotal incision should be packed with sterile gauze packing and sutured closed. Adjunctive therapy with substances that decrease fibrinolysis, such as aminocaproic acid (100 mg/kg, IV), can also be used. Although packing the incision with gauze may provide adequate hemostasis in some cases, referral should be considered if the hemorrhage does not resolve quickly.

Referral should be considered in cases where the source of hemorrhage cannot be identified, substantial blood loss has already occurred before the examination, the horse is in hypovolemic shock, or intra-abdominal hemorrhage is suspected. Horses in hypovolemic shock will show clinical signs such as tachycardia, tachypnea, pale mucous membranes, dull mentation, weak pulses, cold extremities, and generalized weakness. It is important to remember that the PCV and total protein values in these horses are often normal initially, and decreases will not be evident for 6 h (total protein) or 12–24 h (PCV). If possible, these horses should be stabilized with IV fluid therapy before transport. Horses with intra-abdominal hemorrhage will show signs of hypovolemic shock, but they may also show signs of colic. The diagnosis can be quickly made by seeing swirling, hyperechoic abdominal fluid on ultrasonographic evaluation. These horses often require general anesthesia to identify and eliminate the source of hemorrhage. All horses with post-castration hemorrhage, regardless of if the source is quickly identified, are at an increased risk for the development of an infection at the surgical site because of the presence of the blood clot (and potentially suture material or gauze packing). Therefore, they should be treated with a course of broad-spectrum antimicrobial therapy.

#### 5. Eventration

Eventration after castration is rare, occurring in only 0.2–2.6% of cases, but it is the complication that is most likely to be fatal. Therefore, referral is always recommended in cases where the intestine is involved.<sup>2,4–7</sup> Horses with omental eventration do not normally require referral. The omentum can be removed by ligation and transection or emasculation, and generally, there are no complications associated with its protrusion. However, it is advisable in these cases to perform a rectal exam to evaluate the size of the internal inguinal rings and ensure that there is no intestinal protrusion through the rings.

Intestinal eventration usually occurs within 4 h of castration, but there are reports of it occurring as

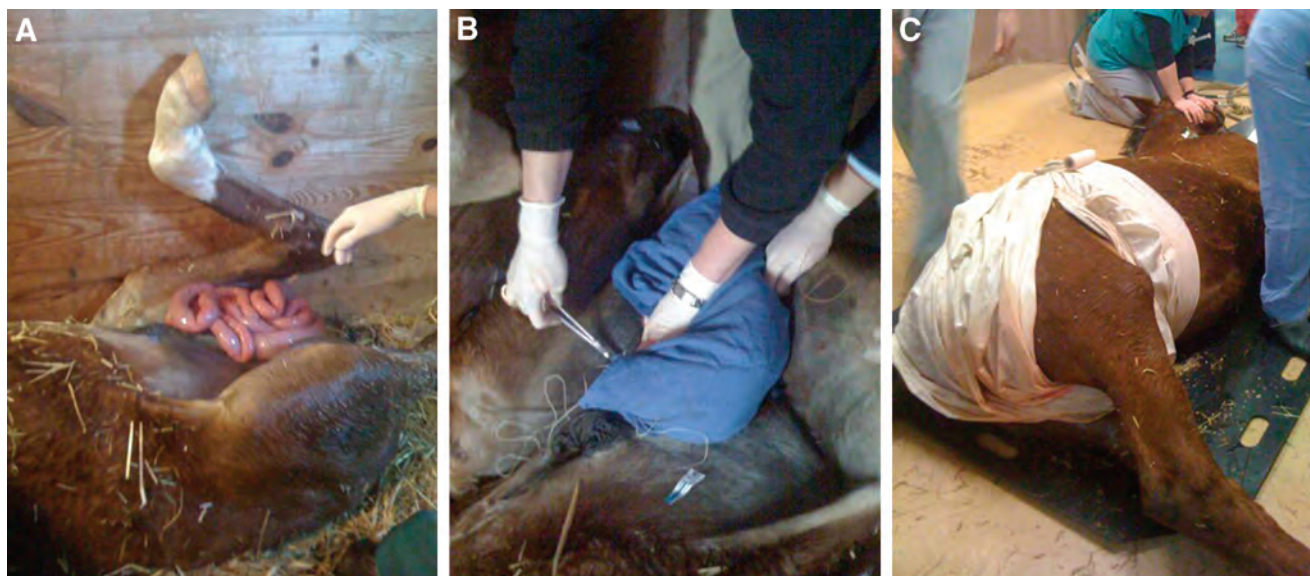

Fig. 3. (A) A yearling that developed small intestinal eventration 4 h after a routine closed castration. Because of the large amount of intestine eventrated, it was not possible to replace it into the scrotum. (B) Therefore, a hand towel was sutured to the skin to form a sling. (C) This was covered with a sheet for additional support during transport to the referral center.

late as 12 days after surgery.<sup>4-7</sup> Risk factors include breed (Standardbreds and Draft Horses are over-represented breeds, and anecdotally, Saddlebreds and Tennessee Walking Horses are also at increased risk), pre-existing inguinal hernias, presence of an inguinal hernia as a foal, and an internal inguinal ring that 2 or more fingers can fit into on rectal palpation. In these cases, it is recommended that a closed or modified open castration with a ligature placed around the cord be performed. A closed castration without a ligature will not decrease the risk of eventration, but the addition of a ligature has been shown to decrease the risk.

After intestinal eventration occurs, initial therapy is aimed at keeping the bowel safe from damage and further contamination and preparing the horse for transport to a referral center. The protruding portion of bowel should be cleaned of all gross contamination with sterile saline and then replaced into the scrotum, which is sutured closed or closed with several towel clamps. If this is not possible because of the amount of bowel that is prolapsed, then a moist towel or drape should be made into a sling and used to support the bowel during transport (Fig. 3). The horse should be given sedation (if systemically stable), broad-spectrum IV antimicrobials, and flunixin meglumine for analgesic and anti-endotoxin therapy. Survival rates after surgical treatment of intestinal eventration range from 36% to 87%, and the lowest survival rates are associated with an inguinal-only surgical approach, increased length of prolapsed bowel, and the need to perform a resection and anastomosis.<sup>6,7</sup>

## 6. Peritonitis

Septic peritonitis rarely occurs after castration; however, the vaginal and peritoneal cavities do communicate, and therefore, the potential for infection to spread from the spermatic cord to the abdomen does exist. Clinical signs of septic peritonitis include fever, depression, tachycardia, dehydration, colic, diarrhea, and anorexia. Abdominocentesis should be performed in horses displaying these signs, and the fluid should be submitted for cytological evaluation, bacterial culture, and sensitivity testing. However, it is important to note that non-septic peritonitis occurs frequently in horses after castration and is not clinically significant, but it will cause the cell count in the abdominal fluid to be elevated; 10,000 cells/ $\mu$ l is common, and counts can reach as high as 100,000 cells/ $\mu$ l for up to 5 days after surgery without causing any clinical signs.<sup>4,5</sup> This is thought to be caused by the inflammation from the presence of blood in the abdominal cavity. Therefore, in horses with clinical signs of peritonitis, it may be more useful to evaluate the fluid cytologically for the presence of bacteria or degenerative neutrophils to make a definitive diagnosis rather than relying on absolute cell counts.

Horses with clinical signs of septic peritonitis should be referred for treatment if possible. This should include broad-spectrum IV antimicrobials (pending the results of culture and sensitivity testing of abdominal fluid), NSAIDs, and anti-endotoxin treatments such as polymixin B and hyperimmune plasma. In severe cases, the placement of an indwelling abdominal drain may be warranted to perform lavage 3-4 times daily. Alternatively, an

exploratory celiotomy can be performed for a more thorough lavage, and a drain can be placed at the time of surgery.

### 7. Penile Damage

Iatrogenic penile damage has been reported after castration and usually occurs when inexperienced veterinarians mistake the penile shaft for a testicle. This can obviously be avoided by having a sound knowledge of the anatomy of the area. If the penis is partially dissected from the surrounding soft tissue while searching for an inguinal or small testicle, then the resultant inflammation and trauma can lead to soft tissue swelling and paraphimosis. In these cases, cold hydrotherapy of the penis and scrotum to reduce the swelling is indicated, and the penis should be manually replaced into the prepuce and then held in place with a sling or purse string suture until the swelling subsides enough for the penis to retract normally. If the penis is inadvertently transected during the procedure, then the horse should be referred for immediate surgical repair or partial phallectomy.

### 8. Hydrocele

A hydrocele is an accumulation of sterile serous fluid within the vaginal cavity that usually occurs months to years after castration. It occurs more commonly after open castrations, and mules are predisposed to developing the condition. Clinically, these horses have a flocculent, non-painful scrotal swelling. Hydroceles generally do not require any treatment unless the owner requests that it be removed for cosmetic purposes or in rare cases, where the swelling is severe enough to cause lameness. Surgical removal under general anesthesia is the treatment of choice, because the swelling will recur after simple drainage alone.

### 9. Conclusions

Although castration complications are relatively common, most of these can be resolved quickly with prompt treatment at the farm. However, complications with acute, life-threatening potential, such as hemorrhage, eventration, and infection or peritonitis with systemic signs of endotoxemia, are true emergencies, and these horses should be considered candidates for referral. Horses with suspected penile damage should also be referred promptly. Other complications may require referral at a later stage if the horses do not respond to the initial therapy attempted at the farm. These include cases with significant or chronic infections and those with peritonitis. Most cases of post-operative swelling and edema can be managed at the farm.

### References and Footnote

1. Mason BJ, Newton JR, Payne RJ, et al. Costs and complications of equine castration: a UK practice-based study comparing "standing nonsutured" and "recumbent sutured" techniques. *Equine Vet J* 2005;37:468–472.
2. Moll HD, Pelzer KD, Pleasant RS, et al. A survey of equine castration complications. *J Equine Vet Sci* 1995;15:522–526.
3. Wilson JF, Quist CF. Professional liability in equine surgery. In: Auer JA, ed. *Equine surgery*, 1st ed. Philadelphia: W.B. Saunders Co., 1992;13–35.
4. May KA, Moll HD. Recognition and management of equine castration complications. *Compend Cont Educ Pract Vet* 2002;24:150–162.
5. Schumacher J. Testis. In: Auer JA, Stick JA, eds. *Equine surgery*, 3rd ed. St. Louis: W.B. Saunders Co., 2006; 775–810.
6. Thomas HL, Zaruby JF, Smith CL, et al. Postcastration eventration in 18 horses: the prognostic indicators for long-term survival (1985–1995). *Can Vet J* 1998;39:764–768.
7. Shoemaker R, Bailey J, Zanzen E, et al. Routine castration in 568 draught colts: incidence of evisceration and omental herniation. *Equine Vet J* 2004;36:336–340.

<sup>a</sup>#1 Vicryl, Ethicon, Somerville, NJ 08876.